

## Use of a **RESIN-IONOMER**

### for Subgingival Restorations (External Root Resorption): Case Report

by Rod Kurthy, DMD

**S**ubgingival restorations are indicated for clinical situations such as external root resorption, fractured teeth, endodontic perforations and root caries. However, there is limited success in these cases due to the nature of the operative field and the working characteristics of the restorative materials. Consequently, many subgingival lesions are considered unrestorable and the teeth – hopeless. External root resorption is a particularly challenging lesion because there is no generally accepted explanation for the condition and traditionally, no effective treatment.<sup>1</sup> However, due to the development of bonding and adhesion, improved materials are now available to offer the clinician new treatment options for subgingival lesions.

In the mid-1990s, Dragoo presented the clinical application of a resin-ionomer (Geristore, DenMat), with emphasis on subgingival and

periodontal applications.<sup>2-4</sup> Geristore's biocompatibility was further investigated<sup>5</sup> and reported as being superior to other materials tested.<sup>6</sup>

*It has been reported that Geristore can be successfully used:*

- For subgingival and periapical lesions<sup>7</sup>
- In close proximity to bone and in areas treated with periodontal regeneration<sup>7</sup>

*Studies reported that Geristore has been successfully used:*

- To treat root perforations<sup>8,9</sup>
- For retrograde restorations<sup>10</sup>
- Furcation lesions<sup>11</sup>
- In association with guided tissue regeneration procedures<sup>12</sup>

The choice of material to restore external root resorption should be based on sound clinical judgment. The requirements of a

restorative material used for subgingival restorations have been defined as:<sup>3,9</sup>

1. Biocompatibility with tooth structures and surrounding periodontal tissues;
2. Adhesiveness to tooth structure even without the use of a bonding system;
3. Dual-cure set;
4. Compactness when set;
5. Radiopaque; and
6. Insoluble in oral fluids.

Among the restorative materials available today, resin-ionomers most closely meet the above requirements. In this case, Geristore was chosen due to clinical reports of excellent biocompatibility.<sup>5,6</sup> Harris<sup>13</sup> reported a gain in clinical attachment in the area of restoration of a cracked tooth with Geristore, confirming a prior report by Anderegge<sup>14</sup> that had similar findings in the area of repair (with resin-ionomer) of a Class III furcation defect in a maxillary molar.

The following case report used Geristore to treat external root resorption.

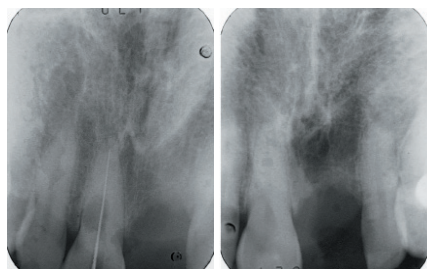


Fig. 1 (left): Large area of root resorption on tooth #11.

Fig. 2: Radiograph taken ten months prior to exam did not demonstrate root resorption.

### Case report

The patient presented with severe discomfort associated with tooth #11. A periapical radiograph was obtained, which revealed a large resorptive lesion (approx. 5.5mm coronapically and 4mm mesiodistally (Figure 1)).

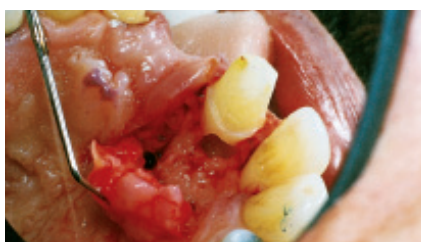Examination with a sharp endodontic explorer determined that the lesion was located on the lingual root surface. The

radiograph taken ten months prior to this examination (Figure 2) revealed absence of this lesion.

The patient was missing tooth #21 and wore a removable appliance referred to as a “flipper”. After a thorough discussion, the patient requested that all attempts be made to retain the affected tooth. It was then decided that a three-unit fixed bridge be fabricated to replace tooth #21.

### Treatment

Initial treatment involved endodontic treatment of tooth #11, bridge abutment preparations and impression taking.



A full-thickness palatal flap was then elevated, and the tissue filling the area of resorption was removed (Figure 3). The internal surfaces of the lesion were “glassy” smooth. To ensure that the lesion was totally free of cellular debris, debridement was carried out using a low-speed handpiece (2,000rpm) and a No. 8 bur.

Phosphoric acid (37 per cent) was applied for ten seconds and rinsed for 40 seconds. The lesion was larger internally than at the root surface, and the apical margin of the lesion extended approximately 2mm below the osseous crest (Figure 4).

The osseous crest was left intact. The lesion was then filled with slow-set Geristore (five minutes auto-cure) without the need for a bonding agent prior to its placement (Figure 5).

Fig. 3: After elevating a full-thickness flap, the tissue filling the area of resorption was removed.

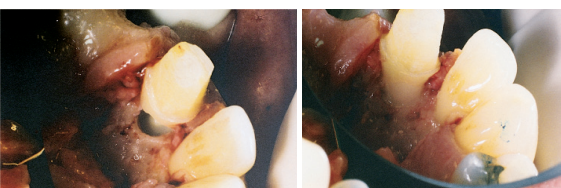

Fig. 4 (left): The lesion was larger internally than at the root surface and extended approximately 2mm below the osseous crest.

Fig. 5: The lesion was filled with slow-set Geristore without the need of a bonding agent.

## Follow-ups

At the one-week post-operative check, the patient reported no discomfort. One week later, the final bridge was cemented and the aesthetic result was good.

Two weeks post-operatively, the probing depths were 1mm to 2mm (Figures 6 & 7). At 13 months after completion of treatment, probing depth was

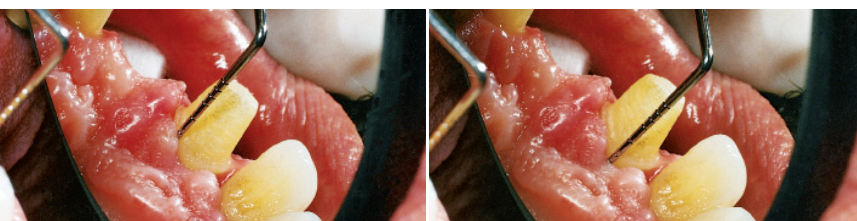


Fig. 6 & 7: At two weeks post-op, probing depths were 1mm to 2mm.

approximately 1mm. There was no evidence of gingival inflammation (as assessed by redness and/or bleeding on probing) at that time (Figure 8).

At nearly two years after completion of treatment, tissue response remained excellent. The palatal sulcus depth in the area of the restoration remained at 1mm without obvious inflammation or additional recession.

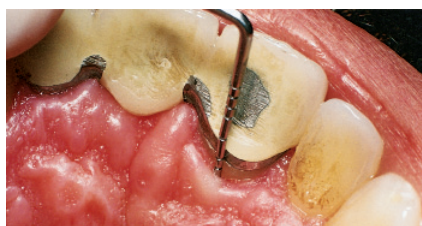


Fig. 8: At 13 months post-op, probing depth was 1mm to 2mm, with excellent tissue response.

## Discussion

External root resorption could be related to chronic inflammation, cysts, benign tumours, trauma, malignant neoplasms and idiopathic conditions.<sup>15</sup> Its pathogenesis has been related to the release of inflammatory mediators, increased vascularity, and pressure.<sup>15</sup> Trauma that causes injury to or necrosis of the periodontal ligament may initiate root resorption.<sup>15</sup>

Two patterns have been reported with regard to idiopathic external root resorption.<sup>15</sup> One pattern reveals resorption occurring on the root surfaces below the gingival epithelial attachment; while the other process starts at the tooth

apex and progresses coronally. The onset or duration of resorption is usually not defined since these lesions are often asymptomatic in the early stages. In this case, it is interesting to note that a significant degree of resorption occurred within ten months.

## Conclusion

This case demonstrated that a resin-ionomer (Geristore) can be used for restoration of a tooth with external root resorption. This restorative material appears to be biocompatible and its application offers restorative options for traditionally difficult-to-treat clinical problems. **DA**

*Reprinted by permission of Dentistry Today, ©2001 Dentistry Today.*

- Resilez-Urioste F, Sanandajt K. Use of a resin-ionomer in the treatment of mechanical root perforation: Report of a case. *Quint Internl.* 1998;29(2):115-118.
- Behnia A, Strassler H, Campbell R. Case report: Repairing iatrogenic root perforations. *JADA.* 2000;131:196-201.
- Murray M, Vertucci F, Nixon E. The sealing ability of retrograde filling materials. Spectrophotometric study. *J Dent Res.* 1998;(1104):243.
- Perry R. Geristore furcation study. Tufts University Dental School (1997). Unpublished data available on request.
- Abitol T, Santi E, Scherer W. Use of a resin-ionomer in guided tissue regeneration: Case reports. *Am J Dent.* 1995;8(5):267-269.
- Harris, RJ. Treatment of a cracked tooth with a resin-ionomer restoration and a connective tissue graft: A case report. *Int J Periodont Rest. Dent.* 2000;20(6):613-617.
- Anderegge, CR. The treatment of Class III maxillary function using a resin-ionomer: A case report. *J Periodontol.* 1998;69:948-950.
- Regezi J, Sciubba J. *Oral Pathol.* Philadelphia, Pa. W.B. Saunders Company; 1989:482-484.

## About the Author



**Dr. Rod Kurthy** graduated with highest honours from Fairleigh Dickinson University School of Dentistry in 1978 and completed a

GP residency at Newark Beth Israel Medical Centre. In addition to his full-time private practice in California, USA, he has 39 years of experience in research and development (in laser and surgical periodontal bone regeneration, endodontic surgery including bone regeneration and repair of resorptive lesions, among others).

Dr. Kurthy has received commendation from the Chief Attorney of the US Department of Defence for his role in supporting patients' rights in disputes with insurance carriers. In March 2005, he was selected as the most respected member of Dentaltown.com by more than 60,000 of his peers.

An international lecturer and author of numerous books and journal articles, Dr. Kurthy has appeared on national media, and has been the personal dentist of the USA Men's World Cup Soccer Team. Most recently, he has been widely known for his remarkable KÖR® Whitening System.

## References

- Shafer W, Hine M, Levy B. *Oral Pathol* 4th ed. Philadelphia, Pa: W.B. Saunders Company; 1983:333.
- Sherer W, Dragoo M. New subgingival restorative procedures with Geristore resin-ionomer. *Practical Periodont Aesthetic Dent.* (Jan/Feb 1995 Supplement).
- Dragoo M. Resin-ionomer and hybrid-ionomer cements: Part I. Comparison of three materials for the treatment of subgingival root lesions. *Int J Periodont Restor Dent.* 1996;16(6):595-601.
- Dragoo M. Resin-ionomer and hybrid-ionomer cements: Part II. Clinical and histologic wound healing responses in specific periodontal lesions. *Int J Periodont Restor Dent.* 1997;17(1):75-87.
- Perry R, Kugel G, McGarry P, et al. An in vivo subcutaneous investigation of a resin ionomer. *J Dent Res.* 1997;(76):326.
- Dennison DK, Keefe TF. Cellular response to various restorative materials. *J Dent Res.* 1996;(75):106.
- Christensen G. Geristore – biocompatible restorative. New concepts video series. C-197c, Practical Clinical Courses.