



CASE REPORT

REPAIRING IATROGENIC ROOT PERFORATIONS

ALI BEHNIA, D.M.D., M.S.; HOWARD E. STRASSLER, D.M.D.; ROBERT CAMPBELL, D.D.S.

A B S T R A C T

Background. Post preparation is an integral part of restoring endodontically treated teeth in indicated cases. Iatrogenic perforation of the root can result from preparing post space and can severely compromise the prognosis of the tooth.

Case Description. Two years after a patient's maxillary lateral incisor was restored with a post-retained composite resin, he went to a dental school emergency clinic with a chief complaint of soft-tissue swelling adjacent to the tooth. The authors took a periapical radiograph that revealed evidence

of a circumscribed radiolucent lesion associated with the distal midroot area and a periapical radiolucency. Based on the radiograph, the authors suspected that the canal preparation for the post and the post placement had perforated the root at the base of the post.

Clinical Implications. The authors used a combined surgical and orthograde approach with a biocompatible restorative material and a clear, plastic light-transmitting post to repair the iatrogenic perforation.

Post placement may be indicated for restoring endodontically treated teeth. Sorensen and Marti-noff¹ indicated that indiscriminate placement of a post in every endodontically treated tooth is unrealistic. When clinicians decide to place a post to retain a core buildup when restoring a pulpless tooth, they need to consider planning for the location, length, shape, post design and placement method.²⁻⁵ The anatomical features of the root—including radicular considerations of root anatomy from a radiographically evident mesiodistal view, as well as the anatomical variations from a facial-lingual standpoint—also influence post preparation and placement. Even on a periapical radiograph, the presence of invaginations or laminations of the roots may not be evident.⁶ Care must be taken when preparing excessively long posts, especially if the root tapers rapidly in the apical area. Also, the clinician must be aware of any root curvatures as

this has a direct influence on post length.⁷

Even with all the factors that must be taken into account when deciding where to place a post, how to prepare the canal and what technique to use, poor clinical judgment still may result in improper orientation of the post space and iatrogenic perforation of the root canal into the attachment apparatus of the tooth. This error is compounded when the clinician is unaware of the mistake and proceeds with the post placement in the perforated root site. The clinical results of this action may go undiscovered until radiographic or clinical evidence of an infection is apparent. The evidence might be the presence of a sinus tract, an abscess or a radiolucency in the area of the perforation.

Post perforations resulting from iatrogenic tooth preparation can be repaired in a variety of ways. The defect can be accessed nonsurgically, surgically or both. It then can be repaired by filling the defect

with a variety of different materials including calcium hydroxide, dental amalgam, Cavit (ESPE), composite resin, glass ionomer cement, freeze-dried bone and tricalcium phosphate.⁸⁻¹⁴

Resin ionomer—a new class of restorative material—has been used recently to treat successfully iatrogenic perforations and resorptive defects.^{15,16} Dragoo described using dual-cure fluoride-releasing adhesive restorative materials. He reported that the resin ionomer had properties that made it an acceptable material to restore subgingival lesions. These properties included but were not limited to histologic evidence of biocompatibility, dual-cure polymerization, adhesion to dentin and cementum, fluoride-releasing, radiopacity, compactness, surface hardness, insolubility in oral fluids, absence of microleakage, low coefficient of thermal expansion and low polymerization shrinkage.

Dragoo described having the most predictable clinical success when using a specific dual-cure resin ionomer—Geristore (Den-Mat). He demonstrated histologic evidence of Geristore's healing ability and connective-tissue adherence in several cases.^{15,16} Resillez-Urisote and colleagues¹² reported using Geristore in the successful treatment of a mechanical root perforation. Sixteen months after the perforation repair, the tooth was healthy and functional. Roth¹⁷ described the successful management of two cases that involved iatrogenic perforations of endodontically treated teeth with Geristore.

When sealing a root perforation that has limited access from within the root canal or

pulp chamber, how to properly manage the restorative material becomes a problem. In these cases, a combined surgical and nonsurgical approach can be used.

In the following case report, we present a novel approach for sealing and restoring a root perforation.

CASE REPORT

A 28-year-old male patient came to the emergency clinic at the University of Maryland at

We suspected that the canal preparation for the post and the post placement had perforated the root at the base of the post.

Baltimore School of Dentistry with a chief complaint of “swelling and pain in the upper jaw.” The patient had not had routine dental care for approximately two years at which time he had his maxillary anterior teeth restored with composite resin and a post placed in his maxillary right lateral incisor.

We conducted an intraoral examination and found localized swelling in the maxillary facial vestibule with a more pronounced swelling adjacent to the maxillary right lateral incisor. There were no probing depths greater than 3 millimeters, and the inflamed areas were consistent with a diagnosis of moderate gingivitis. The examination also revealed that the incisor was extremely sensitive to palpation and percussion.

We took a periapical radiograph that revealed evidence

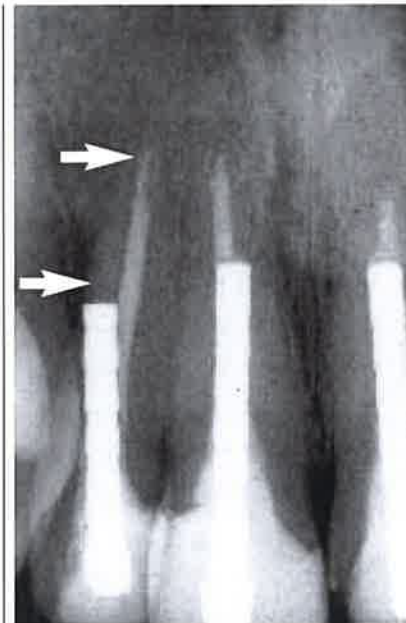


Figure 1. Preoperative radiograph at the time of the initial emergency visit. The arrows indicate the radiolucent lesions at the distal midroot area and in the apical area.

of a circumscribed radiolucent lesion associated with the distal midroot area and a periapical radiolucency (Figure 1). The tooth had a history of endodontic treatment and had been restored with a post-retained composite resin. Based on the radiographic evidence, we suspected that the canal preparation for the post and the post placement had perforated the root at the base of the post.

We made a diagnosis of previous root canal therapy and chronic periradicular periodontitis with symptoms combined with lateral root perforation. We gave the patient two treatment options. The first was a combined surgical and nonsurgical intervention for removing the post, sealing the perforation, performing an apicoectomy, and restoring the tooth. The second was extracting the

tooth and replacing it with either a pontic on a three-unit fixed partial denture or a single-tooth implant. The patient chose the first option.

Clinical procedure. We repaired the perforation and performed an apicoectomy in two phases. Phase 1 consisted of retreatment of the maxillary lateral incisor during the initial emergency appointment. Phase 2, performed one week later, after the swelling resolved, consisted of a surgical approach combined with an orthograde repair of the perforation and intracanal reinforcement of the root.

Phase 1. At the emergency visit, we isolated the lateral incisor with a rubber dam. We created a lingual access opening to expose the post so that it could be retrieved. We successfully used an endodontic ultrasonic unit to remove the post. (The use of ultrasonics to successfully remove posts and silver points has been well-documented.¹⁸⁻²⁰ The mechanism for post removal using ultrasonics is the physical disintegration of the post luting agent by the high-energy ultrasonic vibrations of 50,000 counts per second. To loosen the post so that it can be retrieved, the ultrasonic tip is moved around the periphery of the post and cuts through the cement.) After running the tip around the accessible areas of the post, we left it in place on the exposed end of the post for approximately two minutes. The ultrasonic energy was transmitted down the length of the post causing the cement to disintegrate and the post to loosen. We then retrieved the post with a hemostat (Figure 2).

When we removed the post

from the canal, there was evidence of purulence and hemorrhagic drainage from the access opening. As the patient was not anesthetized, he reported immediate relief. We irrigated the root canal with sodium hypochlorite. When there was no longer evidence of drainage, we dried the root canal with paper points. Because of the amount of drainage and swelling, we decided to wait at least a week before attempting

The ultrasonic energy was transmitted down the length of the post causing the cement to disintegrate and the post to loosen.

a combined surgical and orthograde approach to sealing the perforation. We placed a calcium hydroxide paste into the canal to act as an antimicrobial agent, sealed the access opening with a dry cotton pellet and covered it with a temporary filling material.

Phase 2. One week later, the patient returned to the endodontic clinic and had no evidence of swelling; the maxillary anterior area, however, was sensitive to both percussion and palpation. We anesthetized the area and performed a combined surgical and orthograde procedure to seal the perforation. We removed the temporary restorative material from the access opening and reflected a full-thickness intrasulcular flap with a vertical-releasing incision from the distal of the right maxillary canine to the distal of the left maxillary central

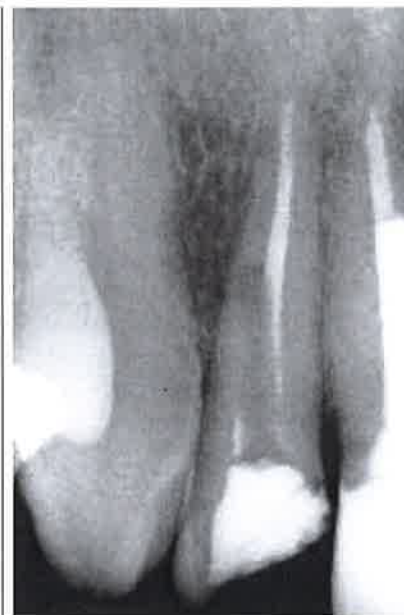

Figure 2. Postoperative radiograph taken after the post was removed.

incisor; we visualized the surgical site using a surgical microscope. Then we enucleated the granulation tissue in the distolateral and apical areas of the maxillary right lateral incisor with a curet and exposed the perforation site using a bone bur.

Before preparing the canal for bonding, we fitted a Luminex Light-Transmitting Post (Dentatus) to the root canal. At the perforation site, we verified that the post was 2 to 3 mm short of it on the distal root surface. We marked the post using an endodontic stopper and removed it.

We etched, rinsed and dried the internal aspect of the root canal, taking care to evacuate both the root canal and the perforation site of the rinsed phosphoric acid etchant. A multiple component A+B primer dentin bonding agent was applied in both the canal and the perforation site using a microapplicator, which we used because it

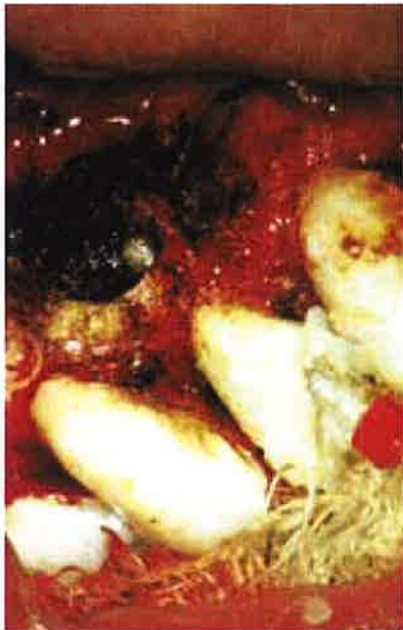

Figure 3. Fitting the clear Luminex Light-Transmitting Post (Den-tatus) after injection of Geristore (Den-Mat).

was small enough to enter the root canal. At the surgically exposed perforation site, we light-cured the adhesive for 10 seconds with a light polymerizing unit. Then we mixed Geristore and loaded it into an Accudose Needle Tube (Centrix) and injected it into the canal from the coronal access opening. Finally, we inserted the Luminex post into the Geristore restorative material to the predetermined length (Figure 3).

The post placement accomplished two objectives. The first was to push the resin into the canal and allow the restorative resin ionomer to be well-adapted to the walls of the root canal. Secondly, the post needed to be centered in the canal so that when it was removed it would leave the appropriate orientation for the prefabricated post's placement. In addition, the post caused a slight excess of the resin ionomer to extrude through the perforation site. We

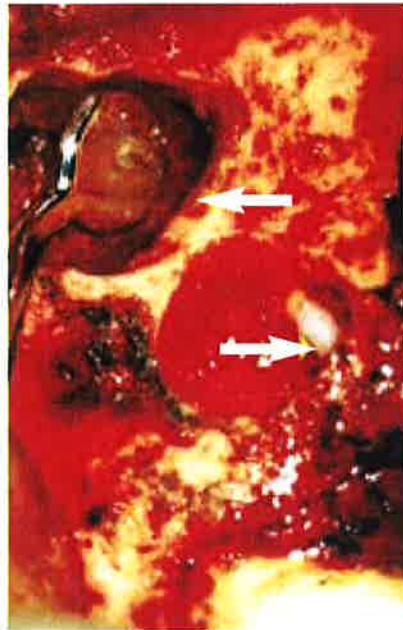


Figure 4. Geristore (Den-Mat) was used to complete an apical retrofill and sealed perforation site (arrows).

light-cured the resin ionomer at this site for one minute. Then we used the light to continue to photopolymerize the Geristore within the canal by placing the

The post needed to be centered in the canal so that when it was removed it would leave the appropriate orientation for the prefabricated post's placement.

light probe at the coronal end of the Luminex post and light-curing it for two minutes. Because Geristore is a dual-cure resin restorative material, photopolymerization allowed for snap set of the restoration at all available sites.

We used a composite resin

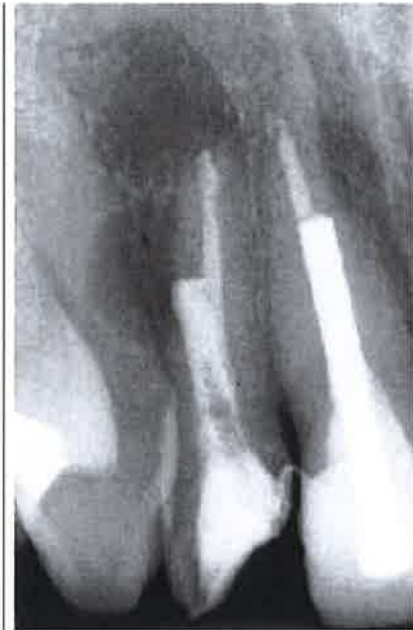

Figure 5. Radiograph immediately after surgery.

finishing bur to remove excess resin ionomer at the perforation site. Then we thoroughly rinsed the site with saline solution to remove any excess resin that remained after finishing of the root surface.

After the lateral perforation was sealed, we performed the apicoectomy by exposing the apical end of the root with a bone bur and resected the apical 3 mm of the root. The root end was prepared using an ultrasonic tip. We completed a retrofill using Geristore following the same adhesive procedure described previously (Figure 4).

The flap was replaced and sutured; no surgical dressing was used. We easily removed the Luminex post, which does not bond to the resin ionomer, from the canal with a hemostat. The access opening was restored using a cotton pellet and temporary filling material. The post space created by the Luminex post allowed for permanent post

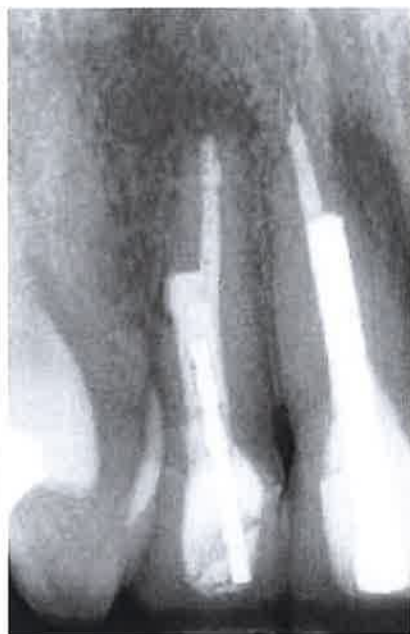

Figure 6. Recall radiograph at one year.

placement at a follow-up appointment (Figure 5).

The postoperative course after the surgery was uneventful. At six weeks after surgery, there were no signs of infection and healing progressed satisfactorily. As part of the final restorative treatment at two months after endodontic therapy and healing, we placed the prefabricated post in the lateral incisor with a composite resin core and prepared, impressed and restored the maxillary tooth with all-ceramic crowns. We



Dr. Behnia is an assistant professor and the director, Pre-doctoral Endodontics, Department of Endodontics, Dental School, University of Maryland at Baltimore, 666 West Baltimore St., Baltimore, Md. 21201. Address reprint requests to Dr. Behnia.



Dr. Strassler is a professor and the director of operative dentistry, Department of Restorative Dentistry, Dental School, University of Maryland at Baltimore.

noted radiographic evidence of healing at both surgical sites at the one-year recall visit (Figure 6).

DISCUSSION

Subosseous root perforations can be difficult to treat.²¹ In many cases, the prognosis of these teeth, even with surgical and restorative treatment is guarded. In this article, we present a novel surgical and orthograde approach to the treatment of a mechanical root perforation. The choice of material used to restore and seal root perforations should be based on sound clinical judgment. We chose to use Geristore based on favorable clinical reports of biocompatibility.^{12,15,16,22}

Also, because we needed to control the placement of the resin ionomer and to place a post to retain the composite resin core, we chose Luminex, which allowed all of the necessary requirements to be fulfilled. The use of the Luminex post for routine restoration of endodontically treated teeth has been described.²³⁻²⁵ In fact, Saupé and colleagues²⁶ have reported the use of a light-transmitting post to polymerize composite resin in a root canal and then to restore the root canal with a post that demonstrated root reinforcement.



Dr. Campbell was a dental student, Dental School, University of Maryland at Baltimore when this article was written. He now is a graduate student, Department of Orthodontics, School of Dentistry, Medical College of Georgia, Augusta.

CONCLUSION

This case report presents the successful treatment of a mechanical root perforation using a surgical approach to visualize the defect. The use of a plastic light-transmitting post cre-

ated a new “root canal” that was later used for the placement of a post and subsequent ceramic crowns to successfully restore the teeth. At the one-year recall appointment, we noted that the lesion had healed. Further investigation is indicated to provide long-term data on the use of this technique. ■

Dr. Strassler is a consultant to Den-Mat and Dentatus.

1. Sorensen JA, Martinoff JT. Intracoronal reinforcement and coronal coverage: a study of endodontically treated teeth. *J Prosthet Dent* 1984;51:780-4.
2. Zillich RM, Corcoran JF. Average maximum post lengths in endodontically treated teeth. *J Prosthet Dent* 1984;52:489-91.
3. Baraban DJ. The restoration of endodontically treated teeth: an update. *J Prosthet Dent* 1988;59:553-8.
4. Christensen GJ. Posts and cores: state of the art. *JADA* 1998;129:96-7.
5. Smith CT, Schuman N. Prefabricated post-and-core systems: an overview. *Compend Contin Educ Dent* 1998;19:1013-22.
6. Gutmann JL. The dentin-root complex: anatomic and biologic considerations in restoring endodontically treated teeth. *J Prosthet Dent* 1992;67:458-67.
7. Perez E, Zillich R, Yaman P. Root curvature locations as indicators of post length in various tooth groups. *Endod Dent Traumatol* 1986;2:58-61.
8. Martin LR, Gilbert B, Dickerson AW. Management of endodontic perforations. *Oral Surg Oral Med Oral Pathol* 1982;54:668-77.
9. ElDeeb ME, ElDeeb M, Tabibi A, Jensen JR. An evaluation of the use of amalgam, Cavit, and calcium hydroxide in the repair of furcation perforations. *J Endod* 1982;8:459-66.
10. Benenati FW, Roane JB, Biggs JT, Simon JH. Recall evaluation of iatrogenic root perforations repaired with amalgam and gutta-percha. *J Endod* 1986;12:161-6.
11. Rud J, Rud V, Munksgaard EC. Retrograde sealing of accidental root perforations with dentin-bonded composite resin. *J Endod* 1998;24:671-7.
12. Resillez-Urioste F, Sanandajit K, Davidson RM. Use of a resin-ionomer in the treatment of mechanical root perforation: report of a case. *Quintessence Int* 1998;29:115-8.
13. Hartwell GR, England MC. Healing of furcation perforations in primate teeth after repair with decalcified freeze-dried bone: a longitudinal study. *J Endod* 1993;19:357-61.
14. Torabinejad M, Hong CU, Lee SJ, Monsef M, Pitt Ford TR. Investigation of mineral trioxide aggregate for root-end filling in dogs. *J Endod* 1995;21:603-8.
15. Drago MR. Resin-ionomer and hybrid-ionomer cements: Part I. Comparison of three materials for the treatment of subgingival root lesions. *Int J Periodont Res Dent* 1996;16:595-601.
16. Drago MR. Resin-ionomer and hybrid-

ionomer cements: Part II. Human clinical and histologic wound healing responses in specific periodontal lesions. *Int J Periodontics Restorative Dent* 1997;17:75-87.

17. Roth JS. Reconstructive endodontics. *Dent Today* 1998;17(1):64-7.

18. Gaffney JL, Lehman JW, Miles MJ. Expanded use of the ultrasonic scaler. *J Endod* 1981;7:228-9.

19. Glick DH, Frank AL. Removal of silver points and fractured posts by ultrasonics. *J Prosthet Dent* 1986;55:212-5.

20. Krell KV, Jordan RD, Madison S, Aquilino S. Using ultrasonic scalers to remove fractured root posts. *J Prosthet Dent*

1986;55:46-9.

21. Santi E, Abitbol T, Scherer W, Palat M. The use of resin ionomer in the regenerative treatment of an interproximal lesion: a case report. *Compend Contin Educ Dent* 1997;18:132-7.

22. Bryan EB, Woollard G, Mitchell WC. Nonsurgical repair of furcal perforations: a literature review. *Gen Dent* 1999;47:274-8.

23. Godder B, Zhukovsky L, Bivona PL, Epelboym D. Rehabilitation of thin-walled roots with light-activated composite resin: a case report. *Compend Contin Educ Dent* 1994;15:54-7.

24. Strassler HE, White M. An adhesive-

esthetic post and core technique. *Esthet Dent Update* 1995;6:34-40.

25. Strassler HE, Mullen K, Buttaro L. An innovative technique for the esthetic restoration and reinforcement of endodontically treated teeth. *Contemp Esthet Rest Practice* 1997;1(5):10-28.

26. Saupé WA, Gluskin AH, Radke RA Jr. A comparative study of fracture resistance between morphological dowel and cores and a resin-reinforced dowel system in the intraradicular restoration of structurally compromised roots. *Quintessence Int* 1996;25:483-91.